

## Histopathological Study of Placenta in Pregnancy Induced Hypertension

Sharvani R. Setty<sup>1</sup>, Sonam S. Nandyal<sup>2</sup>, Narayan Murthy C.<sup>3</sup>, Rekha B. Puranik<sup>4</sup>

<sup>1</sup>Assistant Professor <sup>2</sup>Associate Professor <sup>3</sup>Professor and Head, Department of Pathology, Basaveshwara Medical College and Hospital, Chithradurga, Karnataka 577501, India. <sup>4</sup>Professor, Department of Pathology, Karnataka Institute of Medical Sciences, Hubli, Karnataka 580022, India.

### Abstract

**Context:** Pre-eclampsia is a complication of pregnancy causing both maternal and fetal morbidity and mortality. Changes in the placenta, which are a consequence of some maternal conditions have their bearing on fetal outcome. Studies on placenta from cases of pregnancy induced hypertension (PIH) have shown a spectrum of changes.

**Aim:** To study pathological features of placenta in PIH and to correlate these changes with severity of PIH.

**Methodology:** 100 placentas from cases of PIH and 20 normal placentas were subjected to Gross and microscopic examination. Weight of placenta, infarction, retroplacental hematoma (RPH) and calcification was noted on gross. On microscopy villous changes were quantitated.

**Statistical analysis:** Comparison of parameters between different groups was done by ANOVA test and students "t" test. Categorical data was analysed by chi-square test and Fisher exact probability test.

**Results:** The placental weight was reduced in cases of PIH and they had increased incidence of infarction and RPH compared to controls. There was significant increase in villous lesions like cytotrophoblastic proliferation (CP), syncytial knots (SK), vasculosyncytial membrane paucity (VSMP), thickening of basement membranes (TBM), fibrinoid necrosis (FN) and stromal fibrosis (SF) in cases of PIH. These changes increased with severity of PIH.

**Conclusion:** PIH adversely influences the placenta. Significant gross findings include Infarction and RPH and villous lesions are Increased SK, CP, FN of villi, TBM, VSMP. These changes were proportional to the severity of disease.

**Keywords:** Pregnancy Induced Hypertension; Placenta; Syncytial Knots.

### Corresponding Author:

**Sonam S. Nandyal**, Associate Professor,  
Dept of Pathology, Basaveshwara Medical  
College and Hospital, Chithradurga,  
Karnataka 577501, India.

E-mail: [sonamsnandyal@gmail.com](mailto:sonamsnandyal@gmail.com)

Received on 06.01.2019,

Accepted on 22.01.2019

### How to cite this article:

Sharvani R. Setty, Sonam S. Nandyal, Narayan Murthy C. et al. Histopathological Study of Placenta in Pregnancy Induced Hypertension. Indian J Pathol Res Pract. 2019;8(1):97-105.

## Introduction

The genesis of embryo, the growth of fetus and birth of baby has always fascinated the medical mind. In this seemingly natural process one organ that rarely receives its due, and is often forgotten with the first cry of baby is the placenta. It is the lifeline of the fetus throughout pregnancy and is at times called the diary of intrauterine life. Placenta has been described as the mirror of perinatal mortality. Changes in the placenta, which are a consequence of some maternal condition have their bearing on fetal outcome[1].

Pre eclampsia is a pregnancy complication affecting approximately 5 to 8% of pregnant women and is a significant cause of maternal death, low birth weight, and perinatal mortality in developing countries [2]. Various studies on placentas from cases of pre eclampsia and eclampsia have shown a spectrum of changes both grossly and microscopically [3,4]. Though these changes are not very specific to pre eclampsia syndrome, the quantification of changes in placenta is essential to correlate with the severity of disease and the outcome, in terms of birth weight and perinatal mortality [5,6].

The present study attempts to evaluate gross findings and various microscopic findings in placenta in cases of PIH and its relation to severity of PIH.

## Materials and Methods

Present study was conducted in Department of Pathology in a tertiary health care hospital, from August 2011 to June 2013. A total of 100 placentae from cases clinically diagnosed as pregnancy induced hypertension and 20 placentae from normal cases, were obtained from patients. Required clinical details were obtained from case records. Cases of chronic hypertension or associated condition like anti phospholipid antibody syndrome, diabetes or severe anemia were excluded. The placentae were collected and were gently expressed so as to remove its blood content and then washed thoroughly under tap water, mopped with dry cotton pad. The placentae collected were fixed in 10% formalin and gross examination was carried out. Tissue bits were given from the center and periphery of placenta, umbilical cord, membranes and also from any grossly abnormal appearing areas. Tissue bits were processed and 5 $\mu$  thick sections taken from paraffin blocks were stained with Haematoxylin and Eosin

(H&E) and studied under light microscopy.

Following parameters were noted on gross examination of placenta.

- Weight
- Diameter and thickness
- Attachment of umbilical cord and its length.
- No. of vessels on cross section of umbilical cord.
- Retroplacental hematoma
- Infarction
- Calcification
- Any other abnormality

On microscopy following histological changes were looked for and quantitated (One hundred villi were counted and these changes were expressed as percentage).

- Cytotrophoblastic proliferation
- Syncytial knots
- Fibrinoid necrosis
- Basement membrane thickening
- Stromal fibrosis
- Vasculosyncytial membrane paucity

Placental changes were correlated with severity of PIH and compared with controls..

*Statistical analysis:* Comparison of various parameters between different study groups was done by ANOVA test and students "t" test. Categorical data was analysed by chi-square test and Fisher exact probability test.

## Results

### *Distribution of Cases*

Out of total cases of PIH, there were 29 cases of Mild PIH, 55 cases of severe PIH and 16 cases of eclampsia. Maximum number of cases were from severe PIH group

1. *Weight of placenta:* In the present study 10% placenta in severe PIH group and 12% placenta in the Eclampsia group weighed less than 300 gms, while none of the placenta in control group weighed <300 gms. Mean placental weight in study group was 421 as compared 503 in the control group. Thus overall placental weight was reduced in the study group (PIH) compared to control group. (Table 1)

**Table 1:** Weight of placenta in different groups in present study.

Weight of placenta	Control	Mild PIH	Severe PIH	Eclampsia
<300 gms	0	0	5(10%)	2(12%)
300-499 gms	4(20%)	20(69%)	42(76.3%)	11(68%)
500 gms or more	16(80%)	9(31%)	8(14.5%)	3(18.7%)

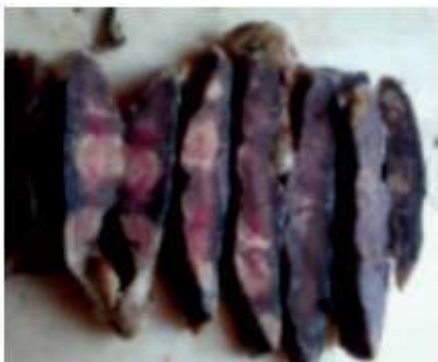**Note:** Numbers in brackets indicate percentage of total no of placenta in each group

2. *Fetoplacental Ratio:* The mean birth weight was 2475, 2098 and 1970 in cases of Mild PIH, severe PIH and Eclampsia respectively, as compared to 2800 in the control group. Mean fetoplacental ratio was 5.4, 5.1 and 4.96 in cases of Mild PIH, severe PIH and Eclampsia respectively, as compared to 5.56 in control group. Reduced birth weight and reduced fetoplacental ratio in severe PIH and eclampsia cases as compared to controls was found to be statistically significant ( $p < 0.05$ ). And decrease in fetoplacental ratio with increase in severity of PIH was noted. (Table 2).

**Table 2:** Mean placental weight, mean birth weight and mean fetoplacental ratio in control group and cases of PIH in present study.

Group	No of cases	Mean placental weight $\pm$ 2SD	Mean birth weight $\pm$ 2SD	Mean fetoplacental ratio
Control	20	503 $\pm$ 36.28	2800 $\pm$ 207	5.56
Mild PE	29	452 $\pm$ 51.5	2475 $\pm$ 329	5.4
Severe PE	55	411.8 $\pm$ 72.5	2098 $\pm$ 531	5.1
Eclampsia	16	397.5 $\pm$ 83.06	1970 $\pm$ 355	4.96

3. *Infarction:* Overall 43% cases in study group (ie cases of PIH) showed infarction involving >5% of placental parenchyma, while none of the cases in control group show infarction >5% (Fig. 1) thus placenta from cases of PIH had increased incidence of infarction compared to normal (Table 3). This difference was found to be statistically highly significant ( $p < 0.001$ ).

**Fig. 1:** Gross: Areas of infarction on cut section of placenta**Table 3:** Showing incidence of infarction in different groups in the present study

Group	Infarction	
	Absent or <5%	>5%
Control	20(100%)	0
Mild PIH	22(75.8%)	7(24%)
Severe PIH	28(50.9%)	27(49%)
Eclampsia	7(43.7%)	9(56%)

4. *Retroplacental hematoma:* In the control group 5% of placenta show retroplacental hematoma while 16% of placenta in the study group show this change, 31% of placenta in eclampsia group showed this change. Therefore incidence of retroplacental hematoma in PIH placenta was increased (Table 4). This difference was not found to be statistically significant. ( $p > 0.05$ ).

**Table 4:** Showing incidence of Retroplacental Hematoma in control group and in cases of PIH in the present study

Group	Retroplacental hematoma	
	Absent	present
Control	19(95%)	1(5%)
Mild PIH	27(93.1%)	2(6.8%)
Severe PIH	46(83.6%)	9(16.3%)
Eclampsia	11(68.7%)	5(31.2%)

### Microscopic findings

On microscopy, findings evaluated and quantitated were cytotrophoblastic proliferation, basement membrane thickening, increased syncytial knots, decreased vasculosyncytial membranes, stromal fibrosis and fibrinoid necrosis.

1. *Cytotrophoblastic proliferation:* Cytotrophoblastic proliferation in the range of 20-40% was found in 20% cases of Mild PIH, 50% cases of Severe PIH, 25% cases of Eclampsia as opposed to 10% cases in controls (Fig. 2). Also 6%, 25.4% and 62.5% cases of Mild PIH, severe PIH and eclampsia respectively showed cytotrophoblastic proliferation in >40% villi. None of the placenta in control group showed cytotrophoblastic proliferation in >40% villi. Percentage of villi showing cytotrophoblastic proliferation increased with increase in severity of PIH (Table 5). This difference was found to be statistically highly significant ( $p < 0.001$ ).

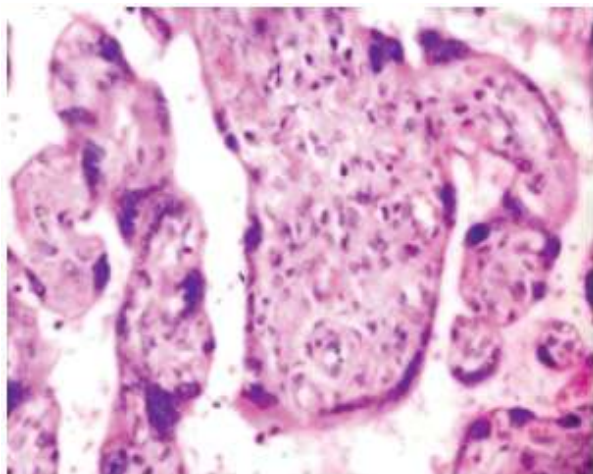


Fig. 2: Cytotrophoblastic proliferation (x40, H and E)

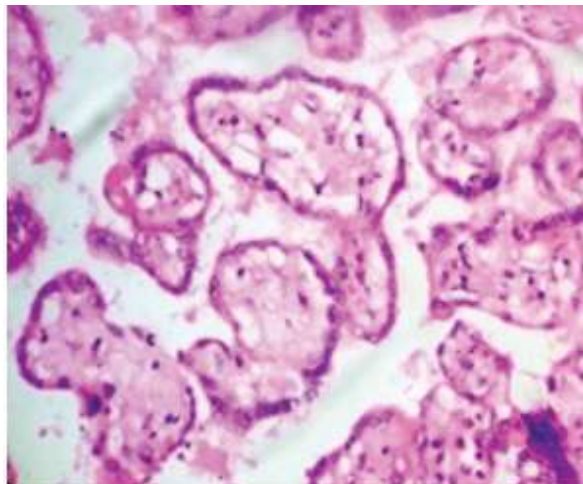


Fig. 3: Basement membrane thickening (x40, Hand E)

**Table 5:** Cytotrophoblastic proliferation observed in control group and cases of PIH in the present study

Microscopic finding		Control	Mild PIH	Severe PIH	Eclampsia
Cytotrophoblastic proliferation	<20%	18(90%)	21(72.4%)	13(23.6%)	2(12.5%)
	20-40%	2(10%)	6(20.6%)	28(50.9%)	4(25%)
	>40%	0	2(6.8%)	14(25.4%)	10(62.5%)

**Table 6:** Basement membrane thickening in control group and in cases of PIH in the present study

Microscopic finding		Control	Mild PIH	Severe PIH	Eclampsia
Basement membrane thickening	<3%	20(100%)	21(72.4%)	20(36.3%)	6(37.5%)
	>3%	0	8(27.5%)	35(63.6%)	10(62.5%)

**Table 7:** Syncytial knots in control group and in cases of PIH in the present study

Microscopic finding		Control	Mild PIH	Severe PIH	Eclampsia
Syncytial knots	<30%	17(85%)	8(27.5%)	10(18.1%)	1(6.25%)
	30-50%	3(15%)	19(65.5%)	31(56.3%)	12(75%)
	>50%	0	2(6.8%)	14(25.4%)	3(18.75%)

**Table 8:** Vasculosyncytial membrane paucity in control group and in cases of PIH in the present study

Microscopic finding		Control	Mild PIH	Severe PIH	Eclampsia
Vasculosyncytial membranes	>30%	18(90%)	21(72.4%)	25(45.4%)	7(43.75%)
	6-30%	2(10%)	7(24.1%)	22(40%)	5(31.7%)
	<6%	0	1(3.4%)	8(27.5%)	4(25%)

**Table 9:** Fibrinoid necrosis in control and in cases of PIH in the present study

Microscopic finding		Control	Mild PIH	Severe PIH	Eclampsia
Fibrinoid necrosis	<3%	17(85%)	14(49%)	12(21.8%)	1(6.25%)
	>3%	3(15%)	15(51%)	43(78.2%)	15(93.7%)

**Table 10 :** Stromal fibrosis in control group and cases of PIH in the present study

Microscopic finding		Control	Mild PIH	Severe PIH	Eclampsia
Stromal fibrosis.	<3%	19(95%)	21(72.4%)	26(47.27%)	8(50%)
	>3%	1(5%)	8(27.5%)	29(52%)	8(50%)

2. *Basement membrane thickening:* Basement membrane thickening in >3% villi was observed in 27.5%, 63.6% and 62.5% cases of Mild PIH, severe PIH and eclampsia respectively (Fig. 3). Overall 47% of placenta in study group showed this change. None of the placenta in the control group show this change (Table 6). This difference was found to be statistically highly significant. ( $p < 0.001$ ).

3. *Syncytial knots:* In the present study it was observed that 30-50% of villi show syncytial knots in 65.5%, 56.3% and 75% cases of Mild PIH, severe PIH and eclampsia respectively, whereas only 15% of cases in control group showed this change (Fig. 4). Also 6.8%, 25.4% and 18.7% cases of Mild PIH, severe PIH and eclampsia respectively showed syncytial knots in >50% villi. None of the placenta in control group show syncytial knots in >50% villi. Thus placenta in PIH cases showed increased syncytial knots (>30%) more often than placenta in the control group (Table 7). This difference was found to be statistically highly significant. ( $p < 0.001$ ).

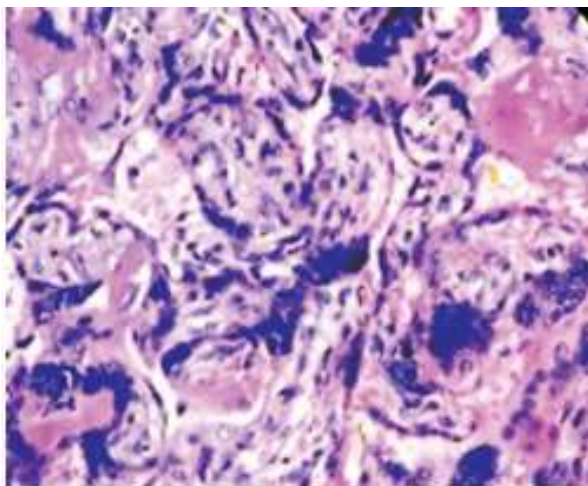


Fig. 4: Syncytial knots (x40, Hand E)

4. *Vasculosyncytial membranes:* Normal placenta usually showed vasculosyncytial membranes in more than 30% of villi. Decreased Vasculosyncytial membranes to the extent of 6 to 30% villi showing VSM was noted in 24.1%, 40% and 31.7% cases of Mild PIH, severe PIH and eclampsia respectively. Whereas only 10% of cases in control group showed this change. Decreased VSM to the extent of <6% villi showing VSM was noted in 3.4%, 27.5% and 25% cases of Mild PIH, severe PIH and eclampsia respectively. Whereas none of the cases in control group show this change. Thus VSM paucity (VSM < 6%) was noted more often in cases of PIH (Table 8). This difference was statistically significant ( $p < 0.05$ ). With increase in severity of PIH this change was

found more often

5. *Fibrinoid Necrosis:* Fibrinoid necrosis in > 3% villi is considered significant and was seen in 15% cases in control group, as opposed to 51%, 78%, 93.7% cases of Mild PIH, severe PIH and eclampsia respectively showing this change. Overall 73% of cases of PIH showed this change (Fig. 5). Thus fibrinoid necrosis was observed more often in the study group as compared to controls. This difference was found to be statistically highly significant ( $p < 0.001$ ). Increase in incidence of fibrinoid necrosis (in >3% villi) with increase in severity of PIH was also noted. (Table 9).

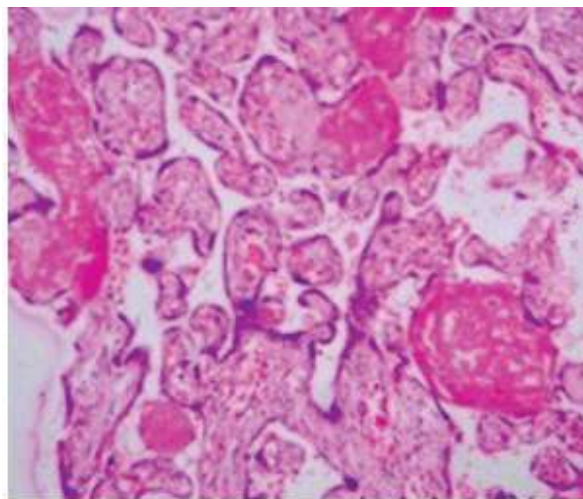


Fig. 5: Villi showing fibrinoid necrosis (x40, H and E)

6. *Stromal fibrosis:* Stromal fibrosis (>3% of villi) was noted in 5% of placenta in control group whereas 27.5%, 52% and 50% of cases of Mild PIH, severe PIH and eclampsia respectively show stromal fibrosis (in >3% villi). Overall 45 cases (45%) of study group showed increased stromal fibrosis (Fig. 6). Thus stromal fibrosis was seen more often in study group more so in severe PIH and eclampsia cases (Table 10). Increase in stromal fibrosis in cases of PIH was statistically highly significant ( $p < 0.001$ ).

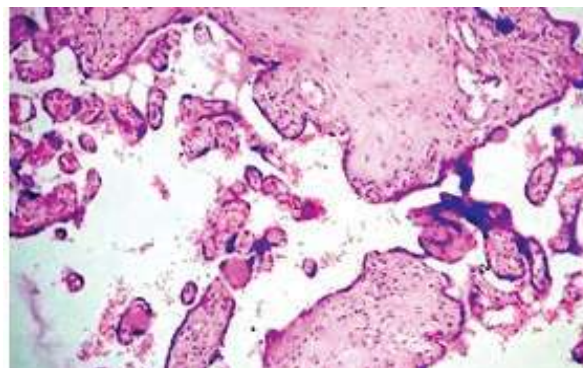


Fig. 6: Villi showing stromal fibrosis (x40, H and E)

**Discussion**

The study of the placenta is, retrospective in nature, yet it provides a reflection of hazards the fetus has been subjected to during its growth and development. It is difficult to define the normal placental findings and differentiate it from the abnormal, because of the structural complexity and rapid evolution of the placenta. Fox H [1] suggested that placental pathology is quantitative rather than qualitative. Benrischke K [7] stressed the significance of placental findings only when these had a bearing on the fetal outcome.

The present study was undertaken to analyse placental changes in PIH with a view to see the spectrum of changes in quantitative terms and to correlate as far as possible, with severity of PIH.

**Gross Findings**

*Weight of the fetus, placenta and F:P ratio:* In the present study the mean placental weight, and the mean fetoplacental ratio in the study group(cases of PIH) was reduced as compared to the control group. Kurdukar MD et al.[4], Das et al. [8], Kher and Zawar [9] also reported similar findings. Sodhi et al. [5] and Bhatia and Sharma [10] also reported reduced placental weight in placentae from PIH group. (Table 11 and 12).

**Table 11:** Mean placental weight- comparison with other studies.

Mean placental weight (gms)	Control	Cases of PIH		
		Mild PIH	Severe PIH	Eclampsia
Present study	503	452	411	397
Kurdukar et al.[4]	475	423	320	364
Das et al. [8]	442	422.5	377.5	355
Kher and Zawar [9]	425		401	

**Table 12:** Fetoplacental ratio - comparison with other studies

Feto-placental ratio	control	Cases of PIH		
		Mild PIH	Severe PIH	Eclampsia
Present study	5.56	5.4	5.1	4.96
Kurdukar et al.[4]	5.9	5.81	4.92	4.78
Das et al.[8]	6.56	6.15	5.43	5.21
Kher and Zawar [9]	7		5.7	

*Infarction:* In the present study 43% cases in study group showed infarction involving >5% of placental parenchyma, while none of the cases in control group showed infarction >5% thus PIH cases have increased incidence of infarction compared to normal. There is increased incidence of infarction with increase in severity of PIH. Similar findings

were also reported by Kurdukar et al. [4], Das B et al. [8], Kher and Zawar [9], Narsimha and Vasudeva [3]. Sodhi S et al. [5] also reported higher incidence of placental infarction in cases of PIH. (Table 13).

**Table 13:** Incidence of Infarction in comparison with other studies.

Infarction >5%	Control	Cases of PIH		
		Mild PIH	Severe PIH	Eclampsia
Present study	0	7(24%)	27(49%)	9(56%)
Kurdukar MD et al. [4]	0	13%	43.7%	40%
Das B et al. [8]	0	40%	65%	55%
Narsimha and Vasudeva [3]	10.8	40.7%	77.7%	55.5%
Kher and Zawar [9]	0	51%	90%	100%
Sodhi S et al. [5]	30%		65%	

*Retroplacental hematoma:* In the present study Retroplacental hematoma was found in 16% cases in PIH group, whereas only 5% of controls had RPH. Similar increase in incidence of RPH in PIH cases was also reported by Mohan H et al. [11], Das B et al. [8], Kurdukar MD et al. [4] and Narsimha and Vasudeva [3]. (Table 14).

**Table 14:** Comparison of incidence of RPH in present study with other studies

RPH	Controls	Cases of PIH		
		Mild PIH	Severe PIH	Eclampsia
Present study	1(5%)	2(6.8%)	9(16.3%)	5(31.2%)
Kurdukar et al.[4]	3%	8.7%	12.5%	20%
Narsimha and Vasudeva [3]	0	0	18.5%	22.2%
Das B et al. [8]	0	10%	15%	5%

*Calcification:* In the present study incidence of calcification was 8% in PIH group and 5% in control group. Mohan H et al. [11] found frequency of calcification was same in control as well as in hypertensive group. Das B et al. [8], Kurdukar MD et al. [4] and Bhatia A et al. [10] found a higher incidence of calcification in placenta from cases of PIH. (Table 15).

**Table 15:** Comparison of incidence of calcification in present study with other studies

Calcification	Control	Cases of PIH		
		Mild PIH	Severe PIH	Eclampsia
Present study	5%	2(6.8%)	4(7.2%)	2(12.5%)
Kurdukar MD et al. [4]	2%	8.7%	12.5%	30%
Das B et al. [8]	30%	35%	45%	45%

### Microscopic Findings

Microscopic findings observed and quantitated were cytotrophoblastic proliferation, basement membrane thickening, syncytial knots, Paucity of vasculosyncytial membranes, Stromal Fibrosis and fibrinoid necrosis.

**Cytotrophoblastic proliferation:** In the present study CP in the range of 20-40% of villi was found in 20% cases of Mild PIH, 50% cases of Severe PIH, 25% cases of Eclampsia as opposed to 10% cases in controls. Also 6%, 25.4% and 62.5% cases of Mild PIH, severe PIH and eclampsia respectively showed CP in >40% villi. None of the placenta in control group show CP in >40% villi. This difference was found to be statistically highly significant ( $p < 0.001$ ). Percentage of villi showing CP increased with increase in severity of PIH. Similar findings were also noted by Kurdukar MD et al. [4], Sodhi S et

al. [5] and Kher and Zawar [9]. Mohan H et al. [11] and Masodkar AR et al. [6] also reported increased CP in placenta of toxemia of pregnancy. (Table 16).

**Basement membrane thickening:** In the present study BMT in >3% villi is observed in 27.5%, 63.6% and 62.5% cases of Mild PIH, severe PIH and eclampsia respectively. Overall 47% of placenta in study group showed this change. None of the placenta in the control group show this change. This difference was found to be statistically highly significant. ( $p < 0.001$ ). Studies by Kurdukar et al. [4], Kher and Zawar [9] and Sodhi et al. [5], also reported increased incidence of BMT (in >3% villi) in cases of PIH along with increased incidence of BMT (in >3% villi) with increase in severity of PIH. Harsh Mohan et al. [11], Masodkar AR et al. [6] and Bhatia A et al. [10] also reported increased BMT in toxemic placenta. (Table 17).

**Table 16:** Comparison of cytotrophoblastic proliferation in present study with other studies

Cytotrophoblastic proliferation	Control	Cases of PIH			
		Mild PIH	Severe PIH	Eclampsia	
Present study	20-40%	2(10%)	6 (20%)	28 (50%)	4 (25%)
	>40%	0	2 (6%)	14 (25.4%)	10 (62.5%)
Kurdukar MD et al. [4]	20-40%	2%	39%	37.5%	30%
	>40%	0	4.3%	62.5%	70%
Kher and Zawar [9]	20-40%	24%	35%	30%	20%
	>40%	0	20%	70%	80%
Sodhi S et al. [5]	>20%	0	60%	83%	100%
Masodkar AR et al. [6]		0		64.2%	

**Table 17:** Comparison of basement membrane thickening (in >3% villi) in present study with other studies

Basement membrane thickening	Control	Cases of PIH			
		Mild PIH	Severe PIH	Eclampsia	
Present study	>3%	0	8(27.5%)	35(63.6%)	10(62.5%)
Sodhi S et al. [5]	>3%	0	40%	83.3%	100%
Kurdukar MD et al. [4]	>3%	4%	21.7%	68.75%	100%
Kher and Zawar [9]	>3%	4%	41%	100%	100%
Masodkar AR et al. [6]	>2%	0		90.4%	
Bhatia A et al. [10]	>4%	0		50%	

**Table 18:** Comparison of incidence of syncytial knots in present study with other studies.

Syncytial knots	Control	Cases of PIH			
		Mild PIH	Severe PIH	Eclampsia	
Present study	30-50%	3(15%)	17(58.6%)	32(58%)	12(75%)
	>50%	0	2(6.8%)	14(25.4%)	3(18.75%)
Kurdukar MD et al. [4]	30-50%	4%	30.4%	37.5%	50%
	>50%	0	4.3%	56.2%	50%
Kher and Zawar [9]	30-50%	8%	34%	40%	40%
	>50%	0	58%	60%	60%
Sodhi S et al. [5]	>30%	5%	40%	66%	100%
Masodkar AR et al. [6]	30-59%	0		57.1%	
	60-89%	0		11.9%	

**Table 19:** Comparison of incidence of paucity of vasculosyncytial membrane in present study with other studies

Paucity of Vasculosyncytial membrane	Control	Cases of PIH			
		Mild PIH	Severe PIH	Eclampsia	
Present study	<6%	0	1 (3.4%)	8 (27.5%)	3 (18.75%)
	6-30%	2 (10%)	7 (24.1%)	22 (40%)	6 (37.5%)
Kher and Zawar [9]	<6%	4%	22%	70%	80%
	6-30%		73%	30%	20%
Sodhi S et al. [5]	<5%	0	50%	100%	75%
Kurdukar MD et al. [4]	<6%	2%	4.35%	62.5%	70%

**Table 20:** Comparison of incidence of Fibrinoid necrosis (in >3% villi) in present study with other studies.

Fibrinoid necrosis	Control	Cases of PIH			
		Mild PIH	Severe PIH	Eclampsia	
Present study	>3%	3 (15%)	15 (51%)	43 (78%)	15 (93.75%)
Kurdukar MD et al. [4]	>3%	6%	34.18%	52.6%	100%
Kher and Zawar [9]	>3%	0	17.6%	40%	20%
Sodhi S et al. [5]	>3%	20%	90%	100%	100%
Masodkar AR et al. [6]	>5%	0		61.9%	
Bhatia A et al. [10]	>4%	0		64%	

**Table 21:** Comparison of incidence of Stromal Fibrosis (in >3% villi) in present study with other studies

Stromal Fibrosis	Control	Cases of PIH		
		Mild PIH	Severe PIH	Eclampsia
Present study	1(5%)	8 (27.5%)	29 (52%)	8 (50%)
Kurdukar MD et al.[4]	6%	21.7%	43.7%	50%
Kher and Zawar [9]	0	23.5	40%	40%
Masodkar AR et al. [6]	0		66.6%	

**Syncytial knots:** In the present study SK were noted in >30% villi in 15% of controls whereas 66%, 73% and 93% cases of Mild PIH, severe PIH and eclampsia respectively showed this change. Thus percentage of placenta showing increased SK (>30%) was significantly increased in the cases of PIH and increases with increase in severity of PIH. Similar findings were also reported by Kurdukar et al. [4], Kher and Zawar [9] and Sodhi et al. [5]. Masodkar AR et al. [6] also reported increased SK in toxemic placenta. (Table 18).

**Paucity of vasculosyncytial membrane:** In the present study paucity of vasculosyncytial membrane (VSM <6% of villi) was noted in 13% cases of PIH, and VSM (in 6-30% of villi) was noted in 34% cases of PIH. This difference was statistically significant. (p<0.05). With increase in severity of PIH this change was found more often. Studies by Kurdukar MD et al.[4], Kher and Zawar [9] and Sodhi S et al. [5], also reported increased incidence of VSMP in cases of PIH along with increased incidence of VSMP with increase in severity of PIH. (Table 19)

**Fibrinoid necrosis:** FN in >3% villi is considered significant and is seen in 15% cases in control group, as opposed to 51%, 78%, 93.7% cases of Mild PIH, severe PIH and eclampsia respectively

showing this change. Overall 73% of cases of PIH showed this change. Thus FN was observed more often in the study group as compared to controls. This difference was found to be statistically highly significant (p<0.001). Increase in incidence of FN (in >3% villi) with increase in severity of PIH was also noted. Studies by Kurdukar MD et al. [4], Kher and Zawar [9] and Sodhi S et al. [5], also reported increased incidence of FN (in >3% villi) in cases of PIH along with increased incidence of FN (in >3% villi) with increase in severity of PIH. Bhatia A et al. [10] and Masodkar AR et al. [6] reported increased incidence of FN (in>4% and >5% of villi respectively) in cases of PIH. (Table 20).

**Stromal Fibrosis:** In the present study SF (>3% of villi) was noted in 5% of placenta in control group whereas 27.5%, 52% and 50% of cases of Mild PIH, severe PIH and eclampsia respectively. Overall 45 cases (45%) of study group showed increased SF. Thus SF is seen more often in study group more so in severe PIH and eclampsia cases. Increase in SF in cases of PIH was statistically highly significant. (p<0.001). Studies by Kurdukar MD et al. [4], Masodkar AR et al. [7] and Kher and Zawar [9] also reported increased incidence of SF (in >3% villi) in cases of PIH. (Table 21).



## Conclusion

From the present study it can be concluded that PIH adversely influences morphology of placenta. Significant pathological changes observed in gross examination of placenta were infarction of placenta (>5% of parenchyma), retroplacental hematoma and calcification. Significant microscopic findings observed were cytotrophoblastic proliferation, basement membrane thickening, increased syncytial knots, Paucity of vasculosyncytial membrane, fibrinoid necrosis and Stromal Fibrosis.

*Conflict of interest:* Nil

## Acknowledgement:

I would like to sincerely thank Dr Sujatha S Giriyan, ( Professor and Head of Department, Department of Pathology, Karnataka Institute of Medical Sciences.) For her constant support and encouragement.

## References

1. Fox H. Pathology of the Placenta. Major problems in pathology. Vol 7 Philadelphia: WB Saunders company Ltd. 1978.
2. Say L, Inoue M, Mills S, Suzuki E. Maternal Mortality in 2005. World Health Organization; Geneva 2005.
3. Narsimha A, Vasudeva DS, Spectrum of changes in placenta in toxemia of pregnancy. Indian J Pathol Microbiol. 2011;54:15-20.
4. Kurdukar MD, Deshpande NM, Shete SS, Zawar MP. Placenta in PIH. Indian J Pathol Microbiol. 2007;50:493-7
5. Sodhi S, Mohan H, Jaiswal TS, Mohan PS, Rathee S. Placental Pathology in Pre-eclampsia Eclampsia Syndrome. Indian J Pathol Microbiol. 1990;33:11
6. Masodkar AR, Kamalkar LR, Patkee PS. Histopathology of placenta and its correlation with fetal outcome. J Obst Gynaec India. 1985;35:294-300.
7. Benirschke K, Kaufmann P. Pathology of human placenta, 2nd edition. springer verlag, 1990.
8. Das B, Dutta D, Chakraborty S, Nath P. Placenta morphology in hypertensive disorders in pregnancy and its correlation with fetal outcome. J Obstet Gynec India. 1996;46:40-6.
9. Kher AV, Zavar MP. Study of Placental Pathology In Toxemia Of Pregnancy And Its Fetal Implications. Indian J Pathol Microbiol. 1981;24:245-51.
10. Bhatia A, Sharma SD, Jalnawalla SF, Sagreiya K. A Comparative study of placenta and fetal outcome. Indian J Pathol Microbiol. 1981;24:277- 83.
11. Mohan H, Sodhi S, Mohan P, Jaiswal PS, Nagpal R, Rathi S. Fetal correlation with placental pathology in toxemia of pregnancy. J Obstet Gynaec India 1989;39:170-5.